

# TIPS & TOOLS

## NORTHERN CATTLE

### How to do a calf necropsy

Valuable information can be obtained from a calf that has recently died. If no veterinary services are available, the following tips may assist in finding the cause. It's important to develop a logical and methodical approach when performing a calf necropsy.

#### Precautions and helpful hints

Before completing the calf necropsy, follow these precautions.

1. Avoid direct contact with tissues and body fluids to limit the risk of contracting zoonotic diseases such as Leptospirosis. The minimum personal protective equipment (PPE) should be elbow-length disposable gloves and a transparent facial shield.
2. Check to see where the mother of the dead calf is, as cows may become aggressive when their calf is being interfered with.
3. Identify the mother so that samples can be collected retrospectively (if needed) next time she is yarded.
4. Select a good spot for disposal (burial or burning) of the carcass when the examination is completed.
5. Refer to *Tips & Tools Assessing animal health status* when performing the necropsy. Follow the methodical steps outlined to ensure all major systems are examined.
6. Observe carefully, take notes and plenty of photographs. If collecting samples, use zip top plastic bags or small clean jars and keep chilled. Record other information such as approximate time of death, seasonal and environmental conditions.
7. If uncertain about doing your own necropsy, place the freshly dead calf in a clean bag, keep as cool as possible and take to your local veterinarian or laboratory if close by.

#### How to complete a calf necropsy

##### Step one: Determine the foetal age

Has the calf been aborted or is it full term? A foetus <8 months of age will have no hair. Foetus size can provide an idea of foetal age (see Table 1).

**Table 1: Determining foetal age (months) by foetus size**

Month	Foetus size similar to
2	Mouse
3	Rat
4	Cat
5	Small dog
6	Medium dog
7	Large dog
8	Calf (with hair)


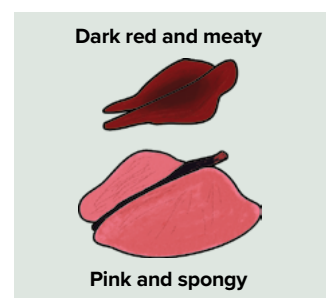


Image: [steerplanet.com/bb/the-big-show/aborted-fetus-pics/](http://steerplanet.com/bb/the-big-show/aborted-fetus-pics/)

##### Step two: Determine if the full-term calf has been born dead or alive

A necropsy will determine if the calf has breathed air. If the lungs are:


- pink and spongy (and float when a section is placed in water), the calf has breathed air
- dark red and meaty, the calf hasn't breathed air.



##### Step three: Determine if the calf has died during a difficult birth (dystocia)

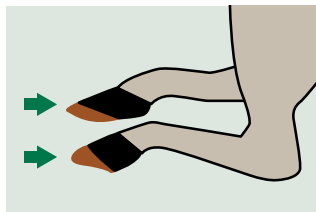
A difficult birth is most common in maiden heifers that deliver their first calf and can be characterised by:

- puffy head
- swollen tongue
- froth in windpipe
- bruising
- haemorrhages and hernias.



### Step four: Determine if the calf was born alive but failed to walk

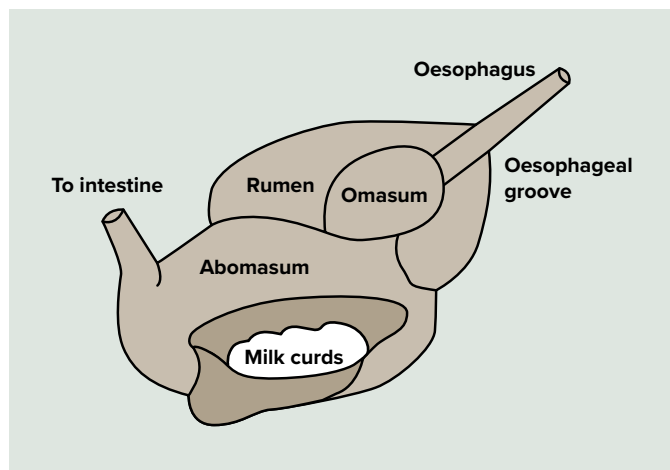
Look for hoof membranes, a soft gelatinous mass covering the bottom of the hoof (preventing damage to the birth canal), to determine if the calf was stillborn or weak at birth.



### Step five: Determine if the calf has suckled the cow

Milk curds in the true stomach (abomasum) of the calf is evidence the calf has suckled. Absence of milk would be indicative of mis-mothering or starvation and/or dehydration (see Figure 1). Colostrum within the first eight hours of life is vital to achieve immunity.

Figure 1: Inspecting the calf stomach

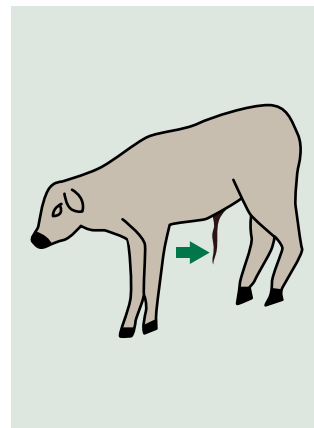


### Step six: Determine how long the calf died after birth

Inspecting the navel cord is a good method to determine how long after birth the calf died.

If the navel cord is:

- prominent, reddish and moist than this suggests the calf died soon after birth
- dark, dry, shriveled and present than this suggests the calf was two to three days old
- oozing and smelly, than navel ill and-or septicaemia is a likely cause of death.



### Step seven: Look for other signs such as a struggle, predation or diarrhoea

Dags around the tail and faecal staining between the hind legs indicates diarrhoea. In baby calves, it can be yellow and pasty or blood tinged.

Signs of dehydration including sunken eyes, dull coat and poor skin elasticity are often associated with diarrhoea, mis-mothering or abandonment.



#### More information

You can download the full Tips & Tools suite at: [mla.com.au/reproductiveperformance](http://mla.com.au/reproductiveperformance), including:

- What joining system should I use?
- How do I manage heifers pre-joining to improve reproductive performance?
- What's causing reproductive loss?
- Assessing animal health status.

#### Geoff Niethe

E: [g.niethe@bigpond.com](mailto:g.niethe@bigpond.com)

#### Nigel Tomkins

E: [ntomkins@mla.com.au](mailto:ntomkins@mla.com.au)

#### Tim Huggins

E: [thuggins@mla.com.au](mailto:thuggins@mla.com.au)

#### Disclaimer

Care is taken to ensure the accuracy of the information contained in this publication. However, MLA cannot accept responsibility for the accuracy or completeness of the information or opinions contained in the publication. You should make your own enquiries before making decisions concerning your interests. MLA accepts no liability for any losses incurred if you rely solely on this publication and excludes all liability as a result of reliance by any person on such information or advice.

Apart from any use permitted under the Copyright Act 1968, all rights are expressly reserved. Requests for further authorisation should be directed to the Content Manager, PO Box 1961, North Sydney, NSW 2059 or [info@mla.com.au](mailto:info@mla.com.au). © Meat & Livestock Australia 2021 ABN 39 081 678 364. Published in January 2021.

MLA acknowledges the matching funds provided by the Australian Government to support the research and development detailed in this publication.

Level 1, 40 Mount Street,  
North Sydney NSW 2060  
P: 1800 023 100  
[mla.com.au](http://mla.com.au)

